

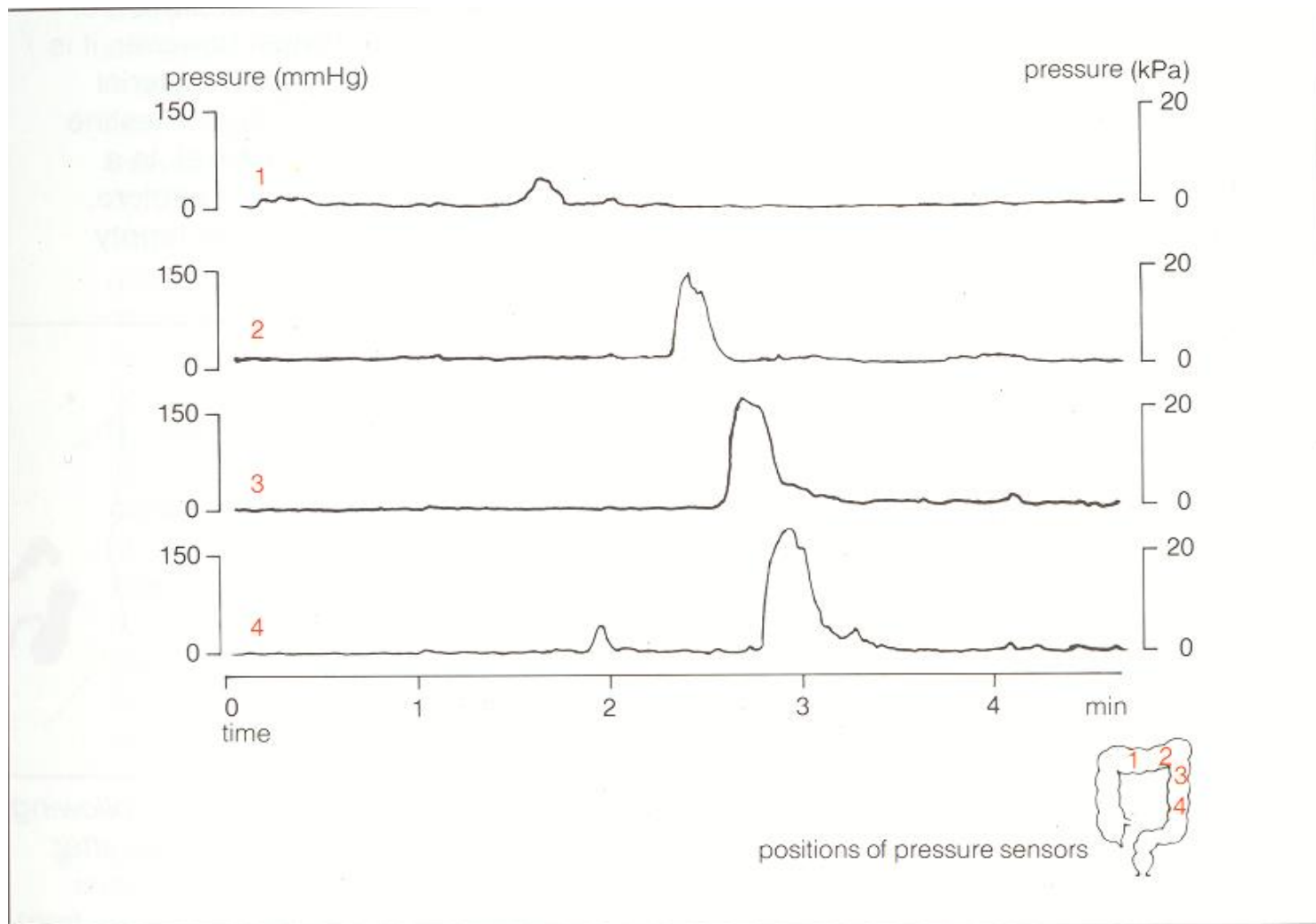
# Functional assessment of the pelvic floor

Dan Carter, MD

Department of gastroenterology

Sheba medical center

## **Colonic motility**



## Colonic mass movements – colon manometry

## **Defecation process - I**

## **Defecation process - II**

## **Defecation process**

# Possible techniques for functional assessment

Investigation	Modality Assessed	Clinical Use
<i>Anorectal manometry</i> Traditional	(1) Anal sphincter function	Established, limited value
	(2) Rectoanal reflexes	Established, limited value
	(3) Rectal sensation (balloon)	Established
	(4) Rectal compliance	Established, limited value
	(5) Defecatory maneuvers	Established
	(6) Saline continence test	Obsolete
High resolution	See (1, 2, and 5 above)	Research
Vector volume	Anal sphincter function, pressure profile	Obsolete
Prolonged ambulatory	Anorectal/rectosigmoid motility	Research
Perineometer	Pelvic floor descent	Obsolete
Perineal dynamometer	Puborectalis function	Research
<i>Barostat studies</i>	(1) Rectal sensation	Established
	(2) Rectal compliance	Established
	(3) Rectal tone, tension	Research
	(4) Rectal capacity	Research
	(5) Rectal motility	Research
<i>Impedance planimetry</i>	Rectal biomechanical properties	Research
<i>Endoanal ultrasound</i>	Two-dimensional imaging of the anal sphincters	Established
	Three-dimensional imaging of the anal sphincters	Research
<i>Endoanal MRI</i>	Imaging of the anal sphincters	Research

## *Neurophysiologic*

Nerve conduction	Pudendal nerve terminal motor latency	Established, limited value
Electromyography	(1) Motor unit action potentials	Established, limited value
	(2) Fiber density	Established, limited value
	(3) Jitter	Research
Evoked potentials	(1) Motor	Research
	(2) Somatosensory	Research
Other	Anocutaneous reflex	Established, limited value
	Strength-duration test	Research

## *Anorectal sensation*

Electrostimulation	(1) Mucosal electrosensitivity	Established, limited value
Thermal stimulation	(2) Mucosal thermosensitivity	Research

## *Rectal evacuation*

Balloon expulsion test	Rectal evacuatory function	Established
Evacuation proctography	Rectal evacuatory function	Established
Scintigraphic proctography	Rectal evacuatory function	Obsolete
Dynamic MRI proctography	Rectal evacuatory function, pelvic organ movement	Research

## *Colonic transit studies*

Radiopaque markers	Global colonic transit	Established
Scintigraphy	Segmental colonic transit	Established, limited value

# Possible techniques for functional assessment

Investigation	Modality Assessed	Clinical Use	
<i>Anorectal manometry</i>	(1) Anal sphincter function	Established, limited value	
	Traditional	(2) Rectoanal reflexes	Established, limited value
		(3) Rectal sensation (balloon)	Established
		(4) Rectal compliance	Established, limited value
		(5) Defecatory maneuvers	Established
		(6) Saline continence test	Obsolete
High resolution	See (1, 2, and 5 above)	Research	
Vector volume	Anal sphincter function, pressure profile	Obsolete	
Prolonged ambulatory	Anorectal/rectosigmoid motility	Research	
Perineometer	Pelvic floor descent	Obsolete	
Perineal dynamometer	Puborectalis function	Research	
<i>Barostat studies</i>	(1) Rectal sensation	Established	
	(2) Rectal compliance	Established	
	(3) Rectal tone, tension	Research	
	(4) Rectal capacity	Research	
	(5) Rectal motility	Research	
<i>Impedance planimetry</i>	Rectal biomechanical properties	Research	
<i>Endoanal ultrasound</i>	Two-dimensional imaging of the anal sphincters	Established	
	Three-dimensional imaging of the anal sphincters	Research	
<i>Endoanal MRI</i>	Imaging of the anal sphincters	Research	

## Neurophysiologic

Nerve conduction	Pudendal nerve terminal motor latency	Established, limited value
Electromyography	(1) Motor unit action potentials	Established, limited value
	(2) Fiber density	Established, limited value
	(3) Jitter	Research
Evoked potentials	(1) Motor	Research
	(2) Somatosensory	Research
Other	Anocutaneous reflex	Established, limited value
	Strength-duration test	Research
<i>Anorectal sensation</i>		
Electrostimulation	(1) Mucosal electrosensitivity	Established, limited value
Thermal stimulation	(2) Mucosal thermosensitivity	Research
<i>Rectal evacuation</i>		
Balloon expulsion test	Rectal evacuatory function	Established
Evacuation proctography	Rectal evacuatory function	Established
Scintigraphic proctography	Rectal evacuatory function	Obsolete
Dynamic MRI proctography	Rectal evacuatory function, pelvic organ movement	Research
<i>Colonic transit studies</i>		
Radiopaque markers	Global colonic transit	Established
Scintigraphy	Segmental colonic transit	Established, limited value



# Anorectal manometry

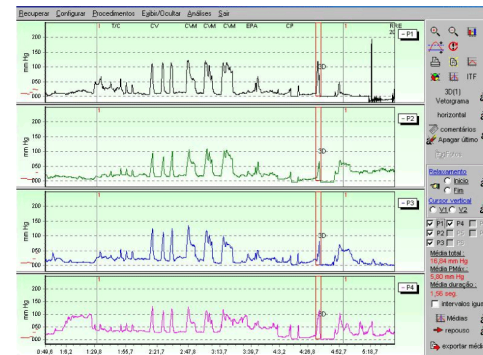
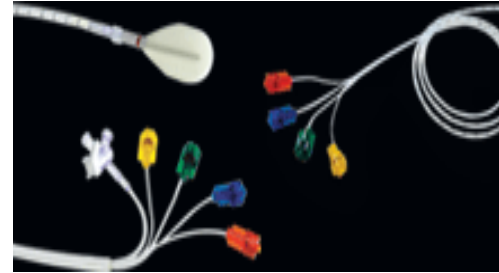
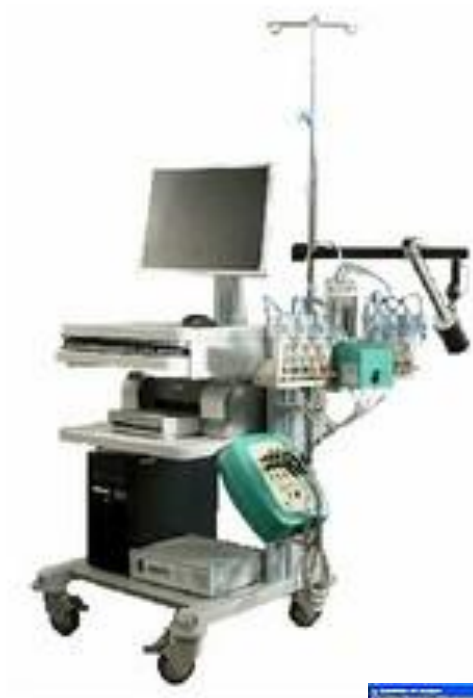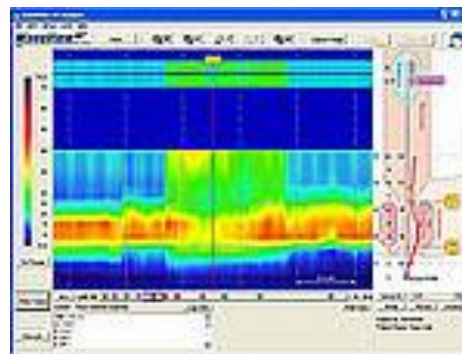
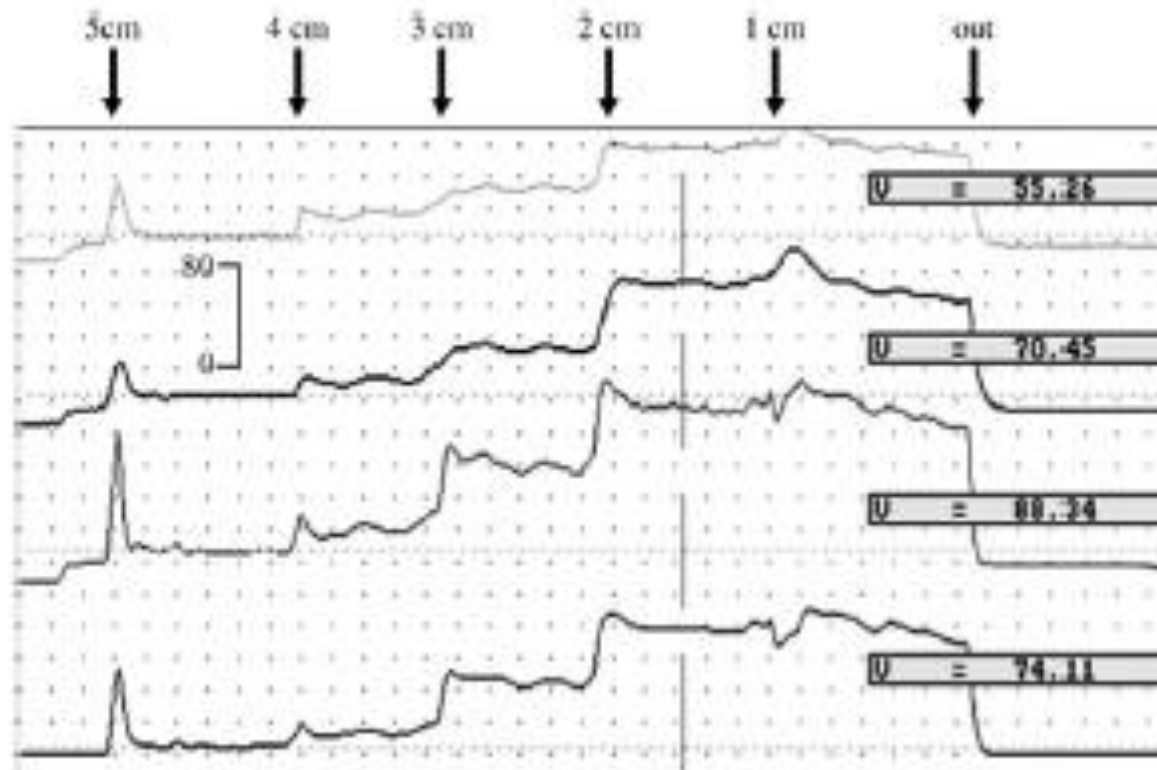


FIGURE 1 – Postoperative anorectal manometry. Patient underwent to MTR

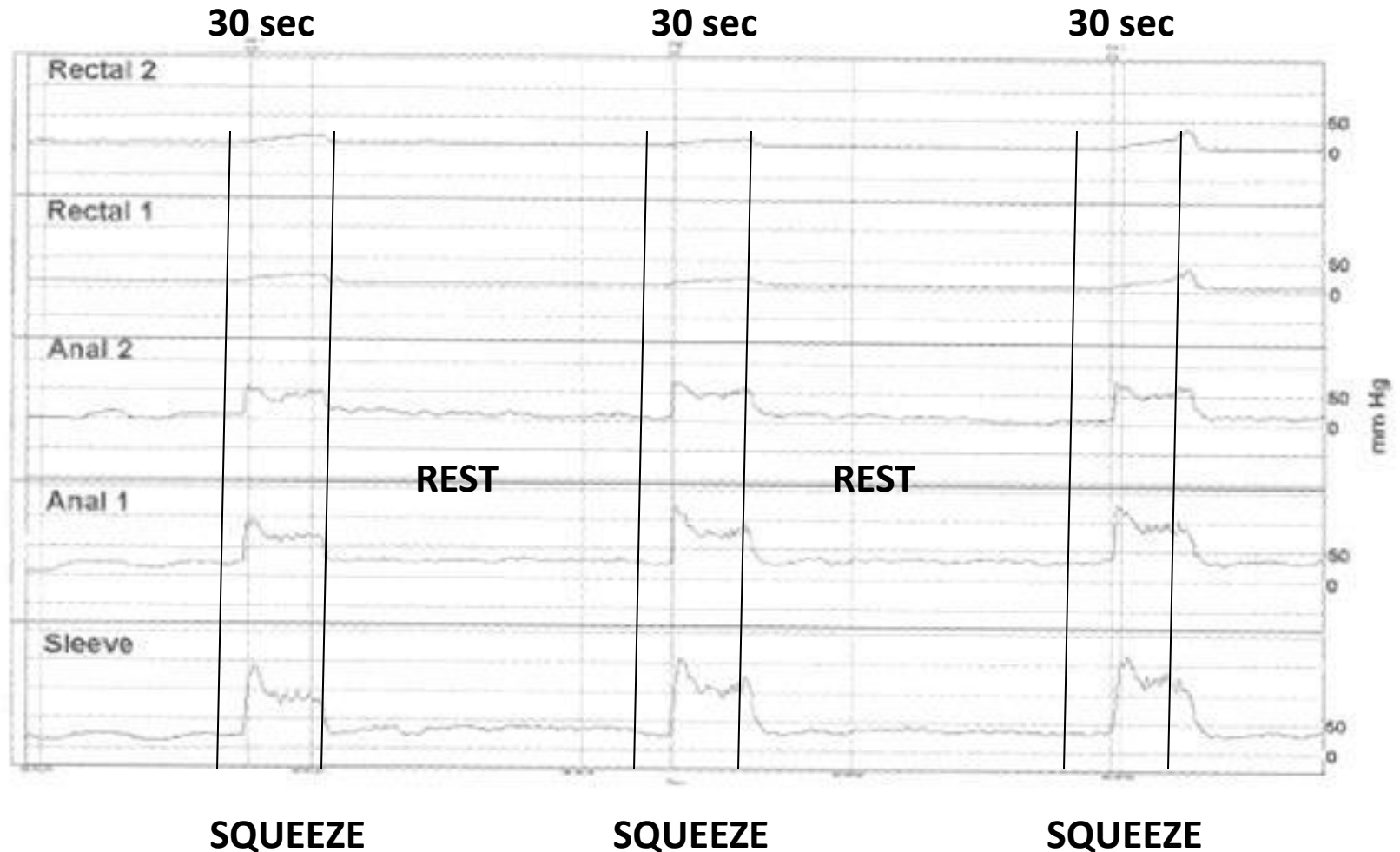


# Pull through anorectal manometry

# Functional anal canal



# Maximal voluntary squeeze pressure



New Study
 Study Wizard
 Demographics
 Traces
 Report
 

1

2

3

»

➡

⬇

⬆

⬇

⬆

⚖

🔄

6

4

2

Anatomical
 

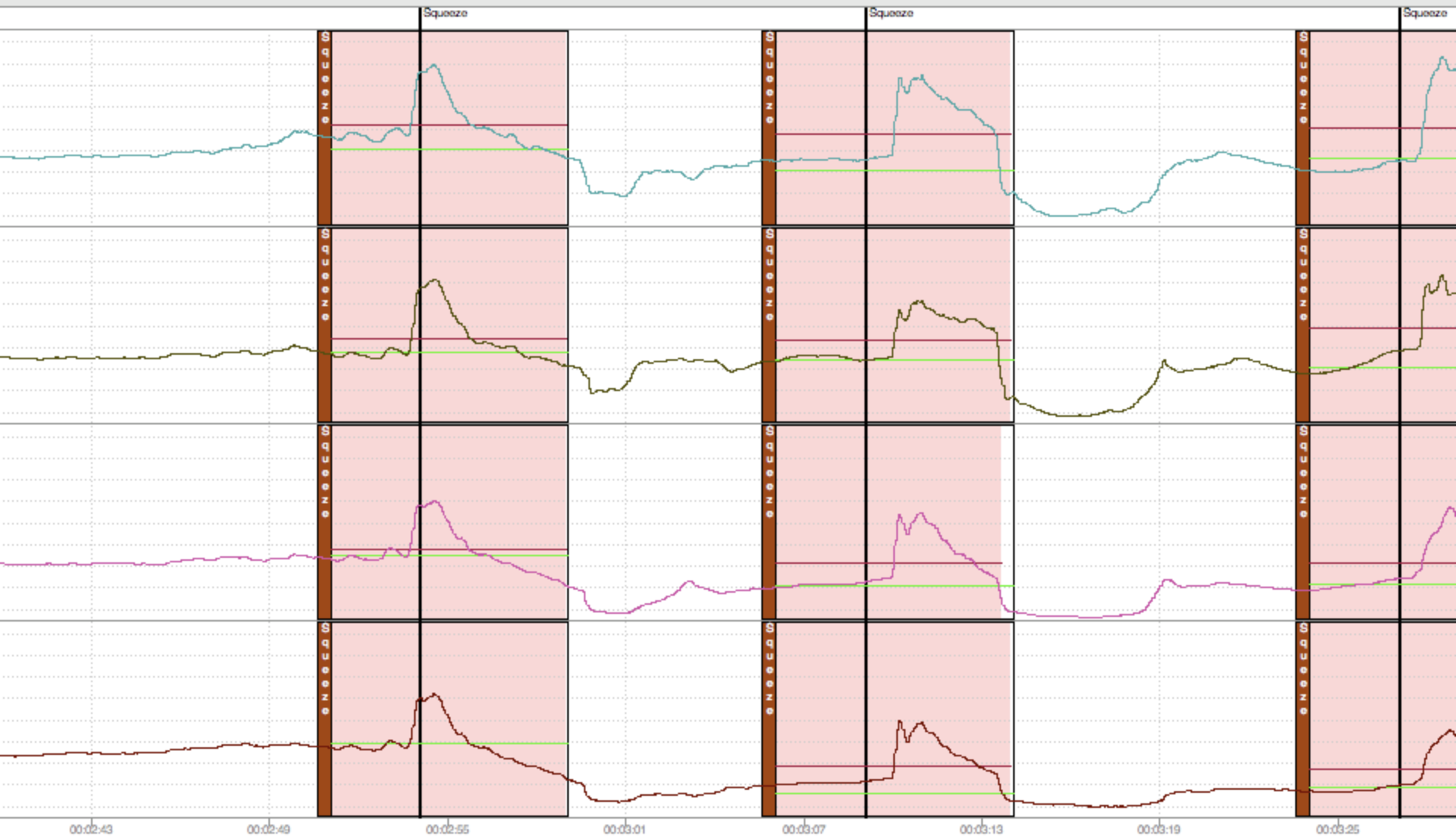
»

↶

↷

Anorectal
 Rest
 Resting
 Squeeze
 Squeeze
 Strain
 Strain
 Cough
 Cough
 +RAIR+
 RAIR
 -RAIR-
 None
 Fin

AFT 9/22/2009



# Rectoanal inhibitory reflex (RIER)

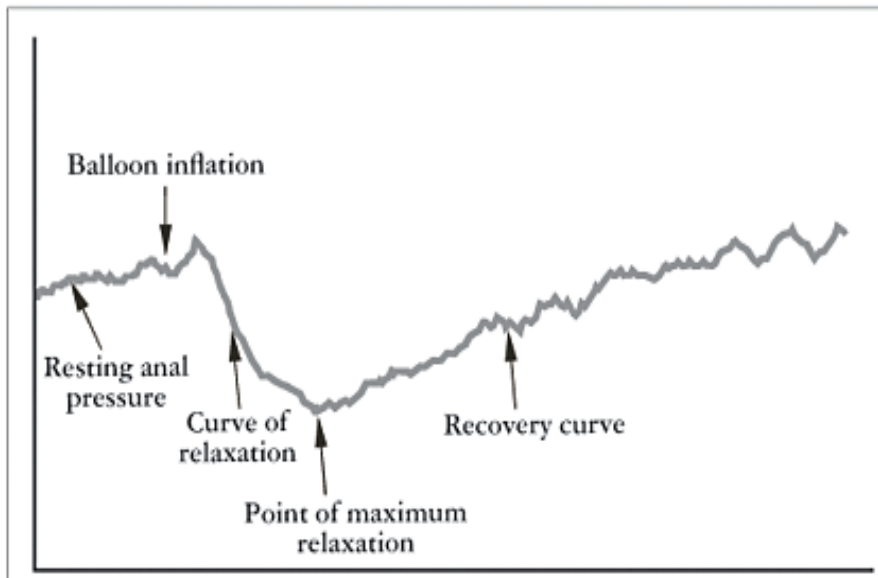
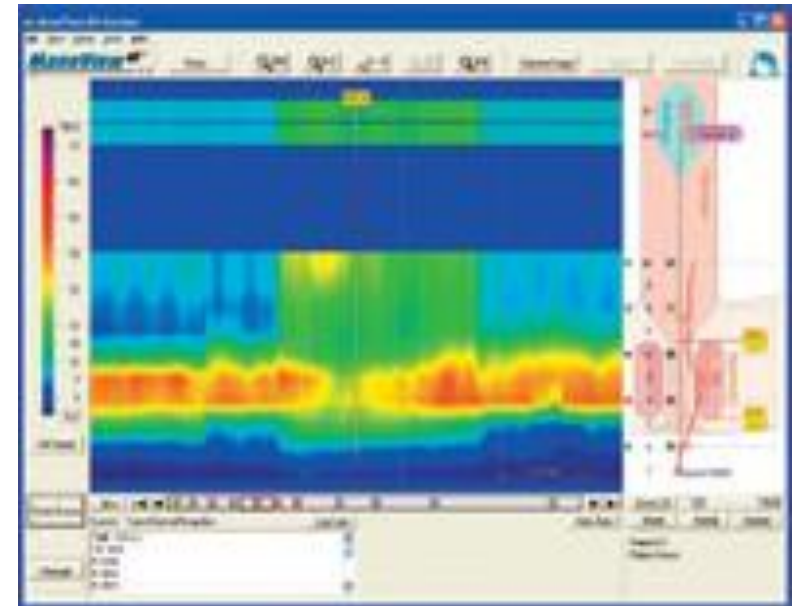
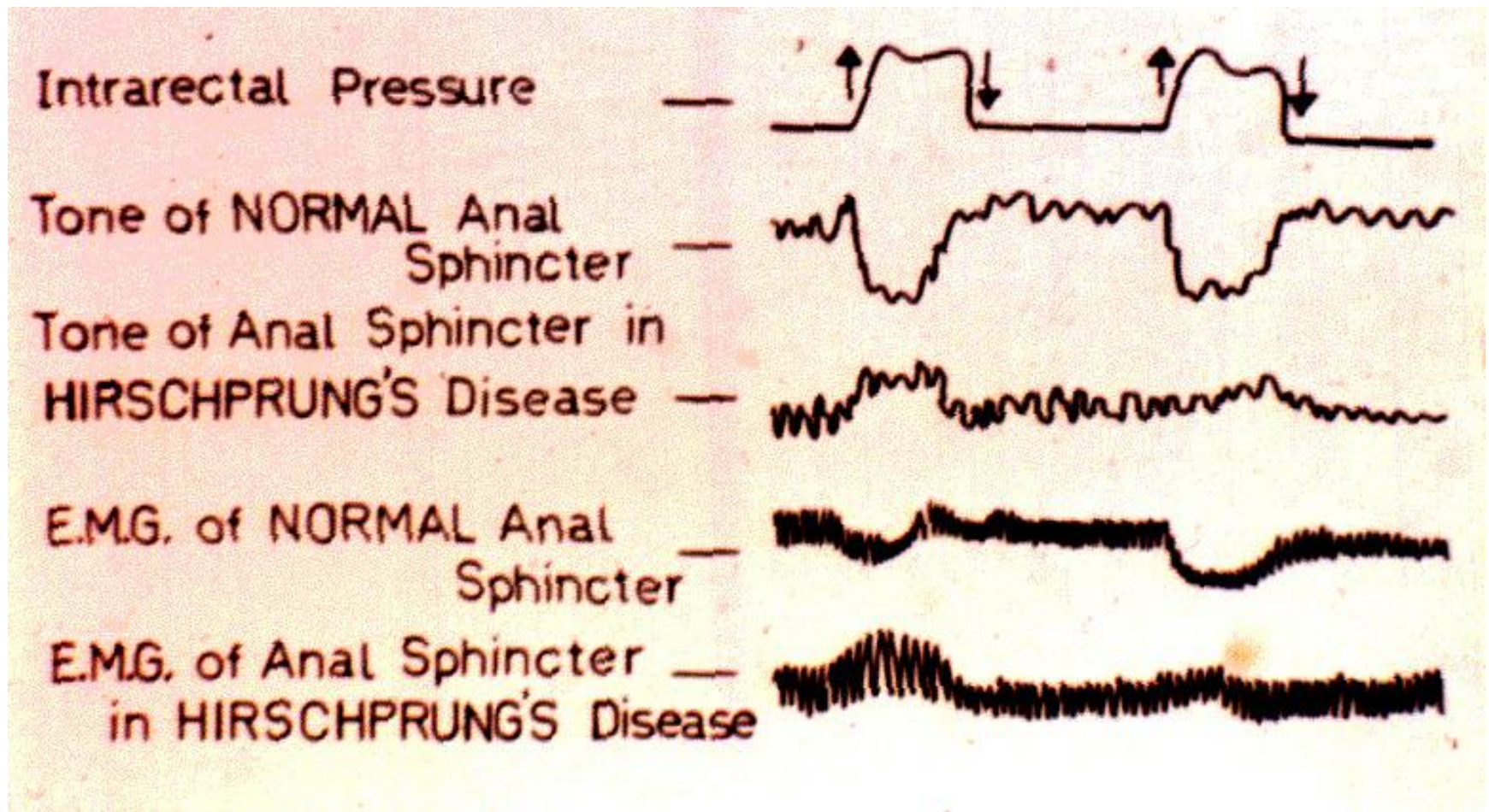


FIGURE 1 - Rectoanal inhibitory reflex





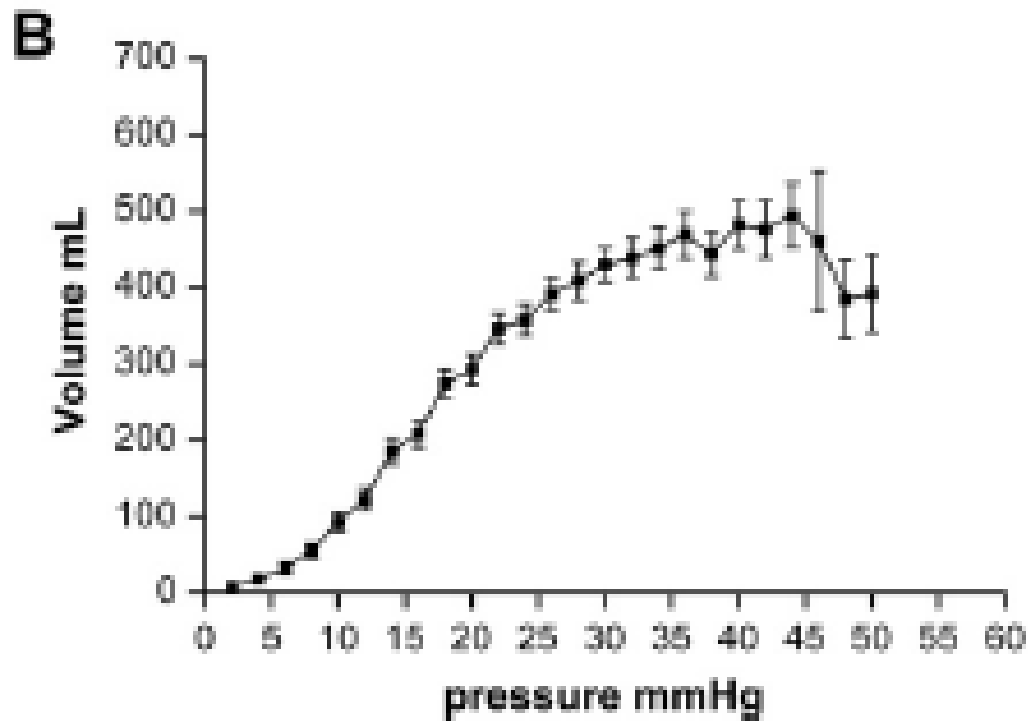
# Abnormal RIER



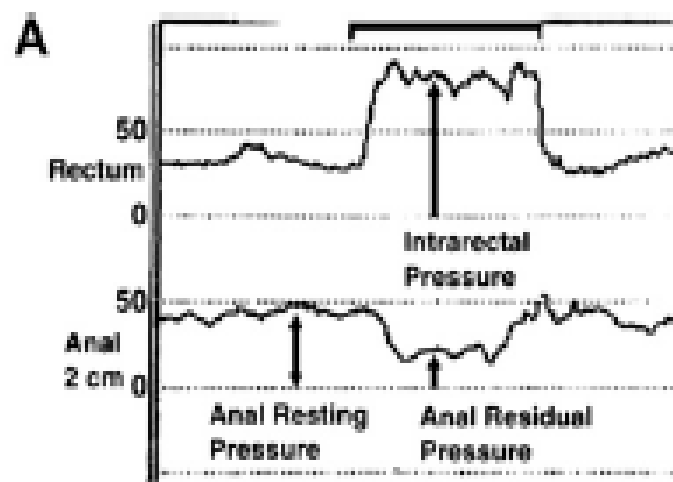
# Rectal sensation



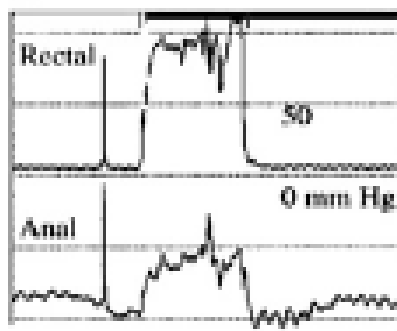
# Rectal compliance




# Dyssnergic defecation



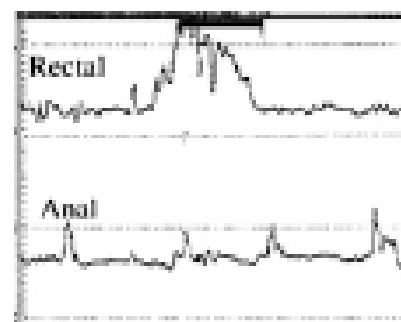
**B**



Type I



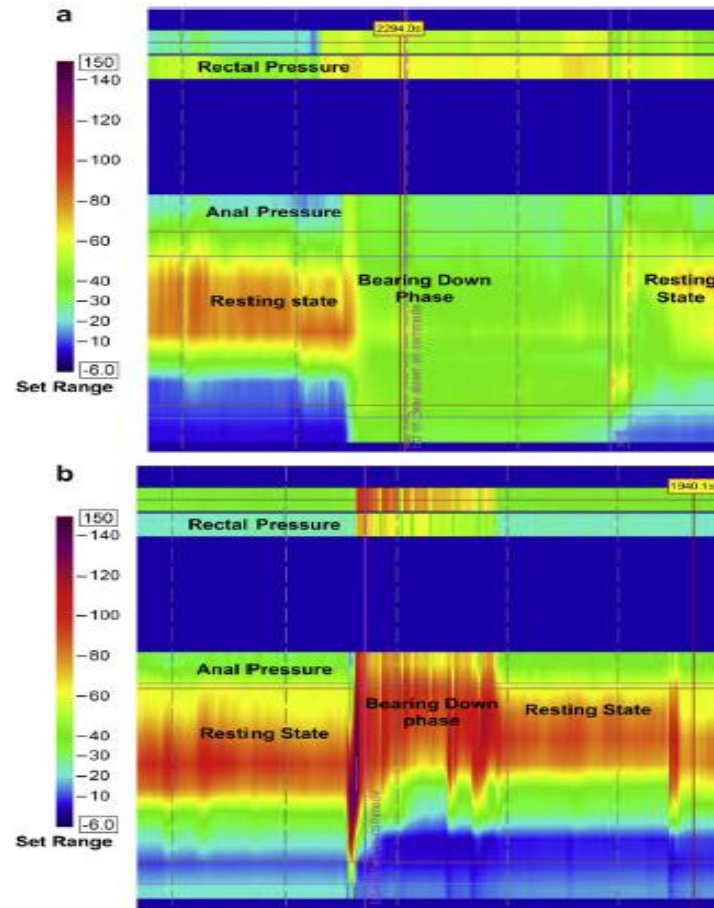
Type II



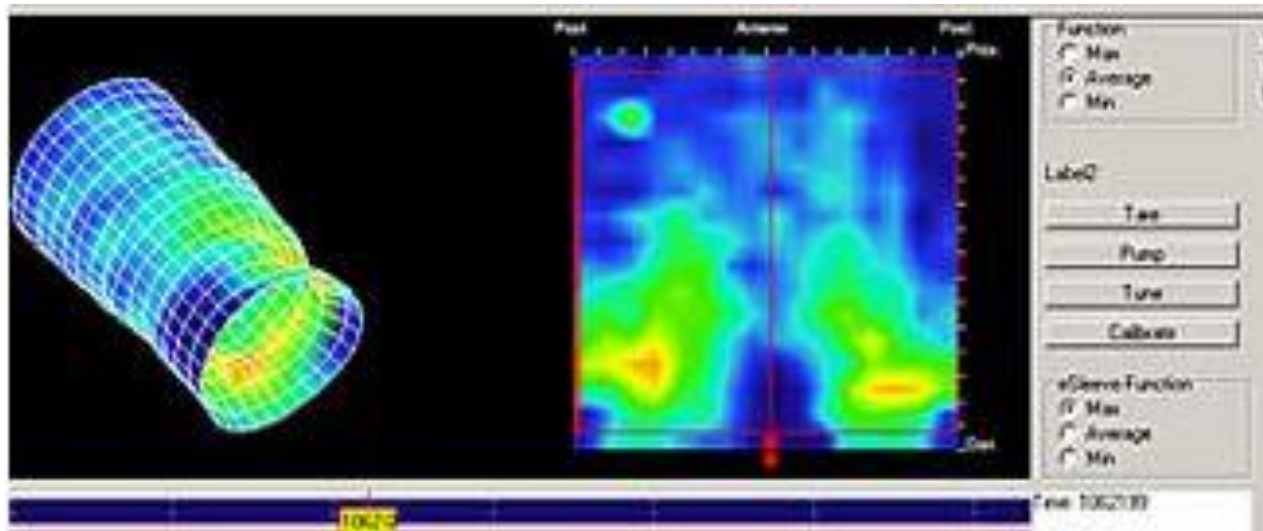
Type III

# Balloon expulsion test

# High resolution manometry



# 3D high definition rectal manometry

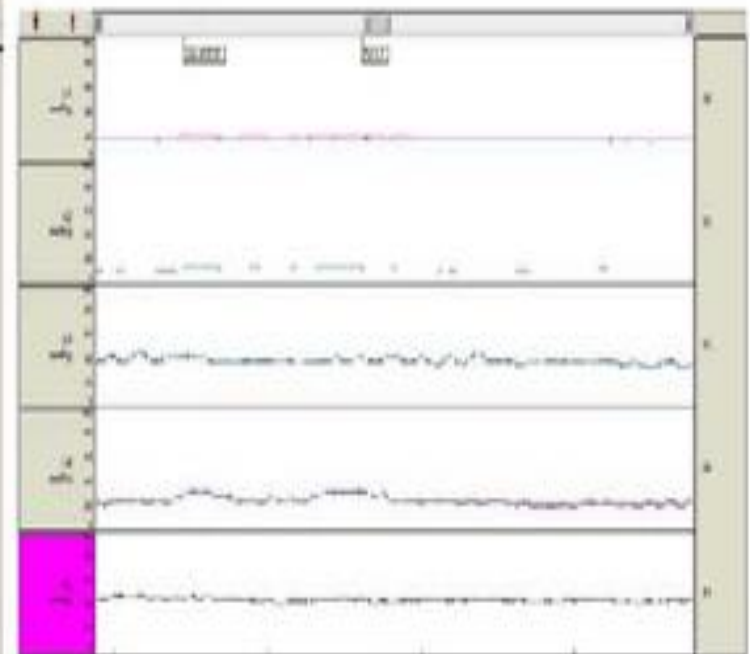
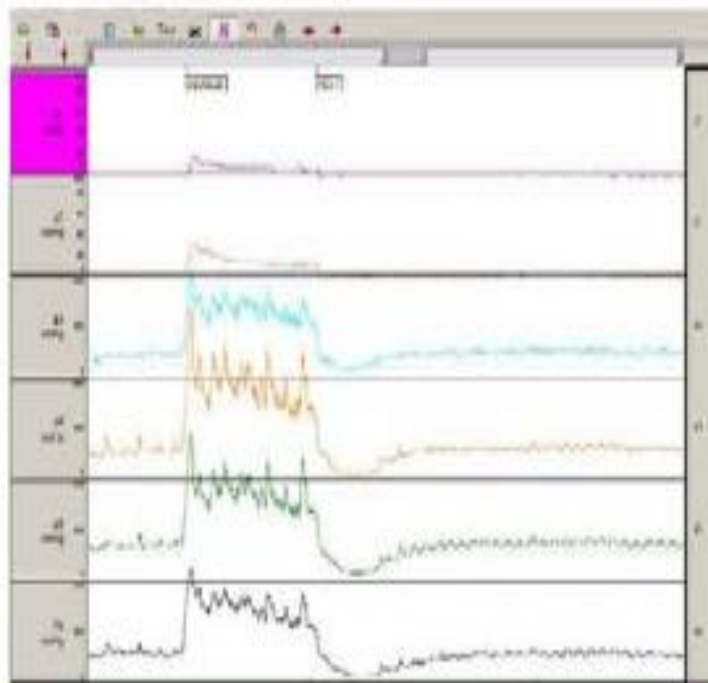


# High definition and standard anorectal manometry in health and fecal incontinence

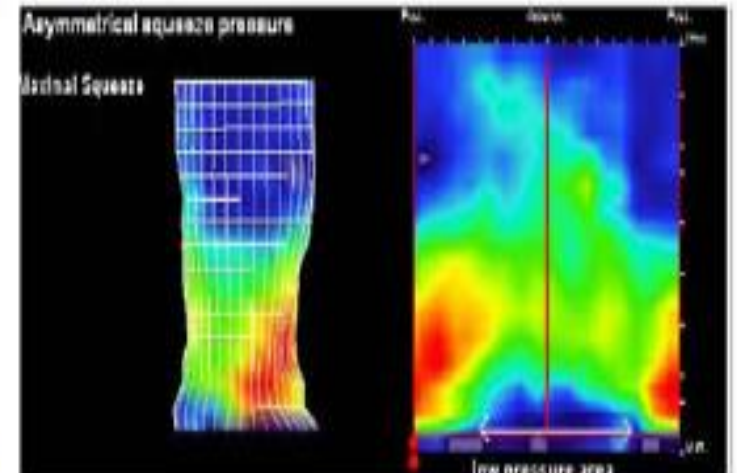
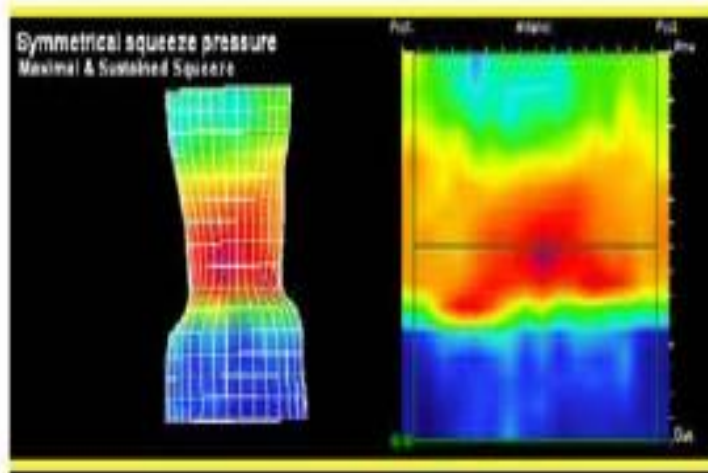
## Healthy

## Fecal incontinence

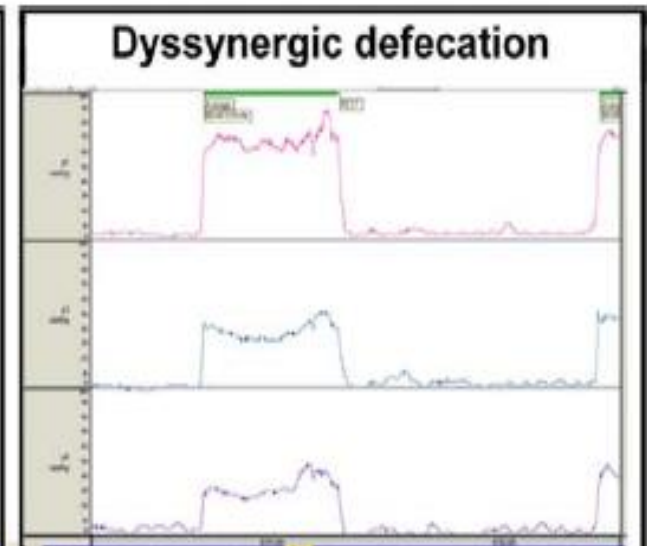
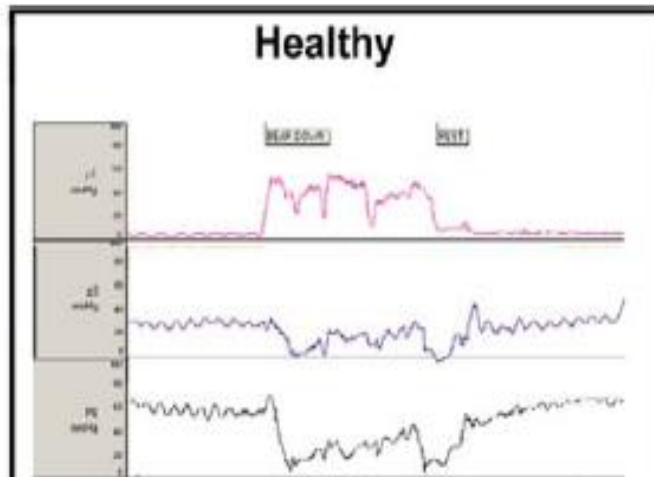
### Anorectal manometry



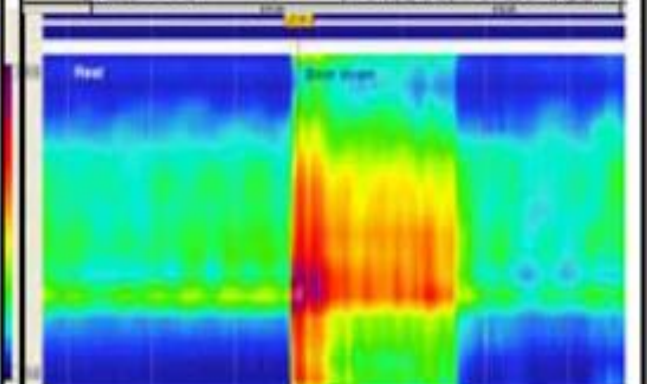

### High definition anorectal pressure topography-3 D



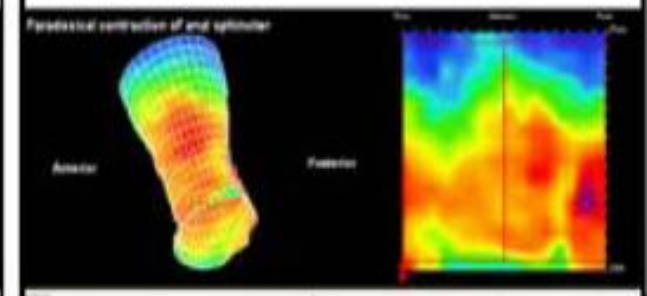

## Anorectal manometry



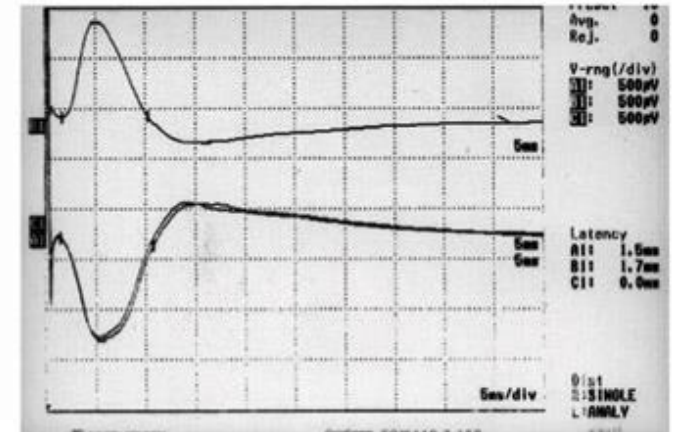
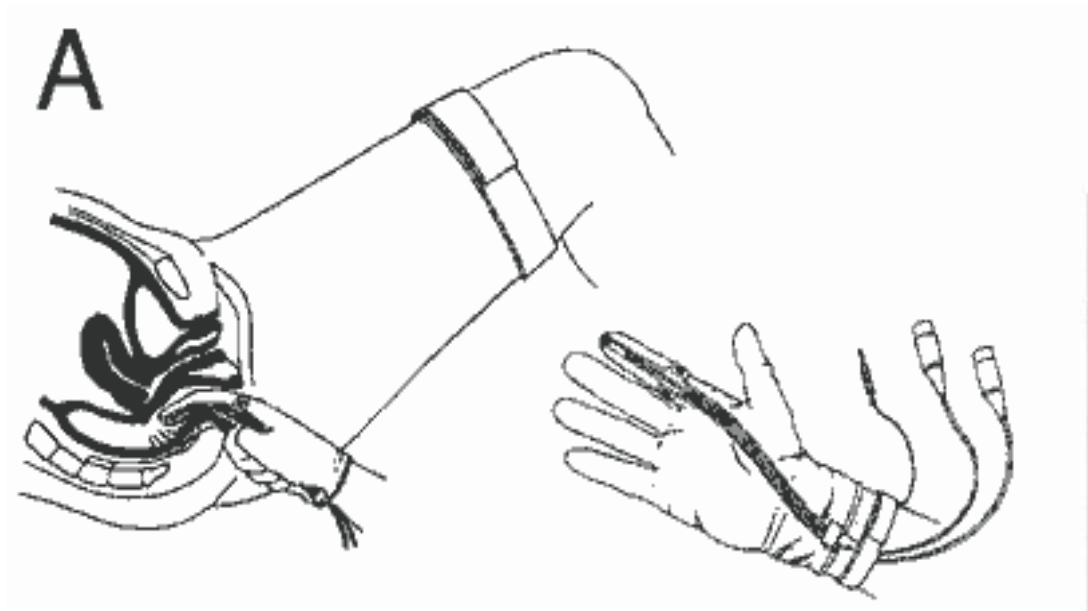
## High resolution anorectal pressure topography-2 D



## High definition anorectal pressure topography-3D

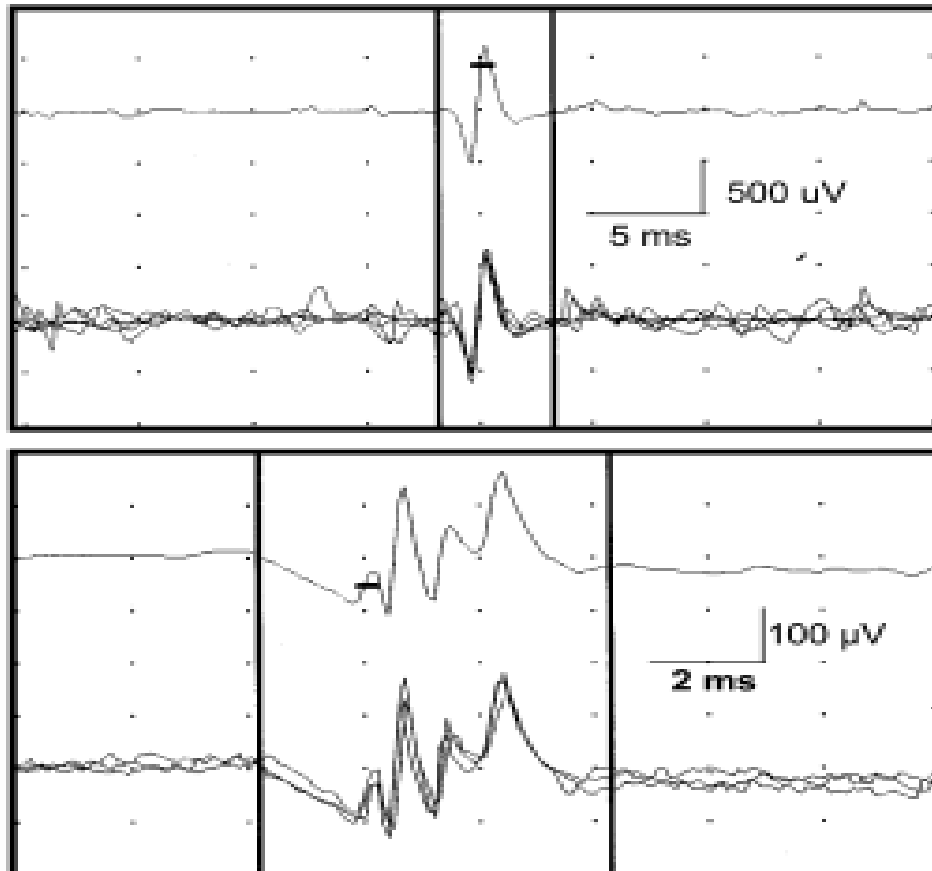


# Pudendal nerve terminal nerve latency

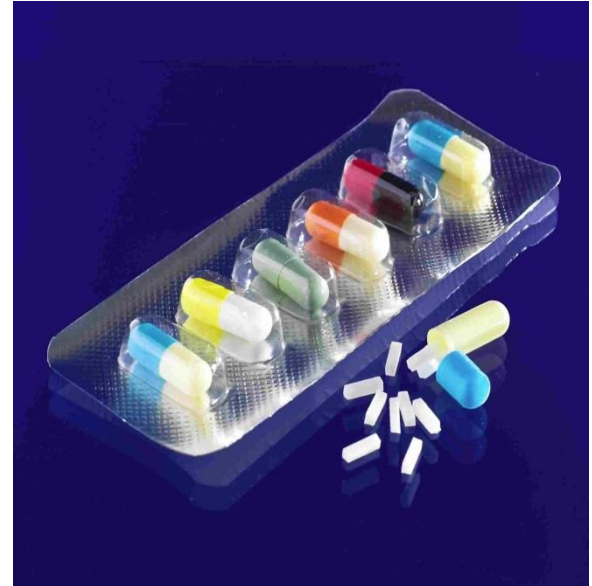
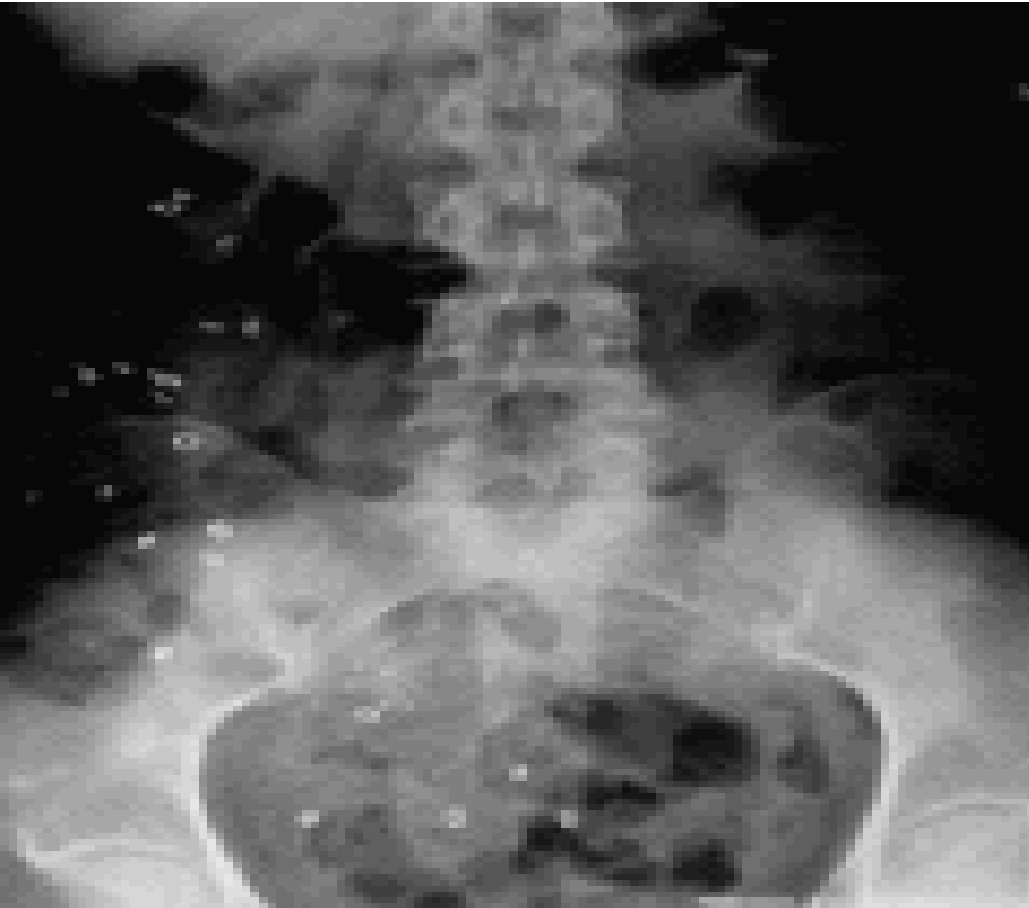


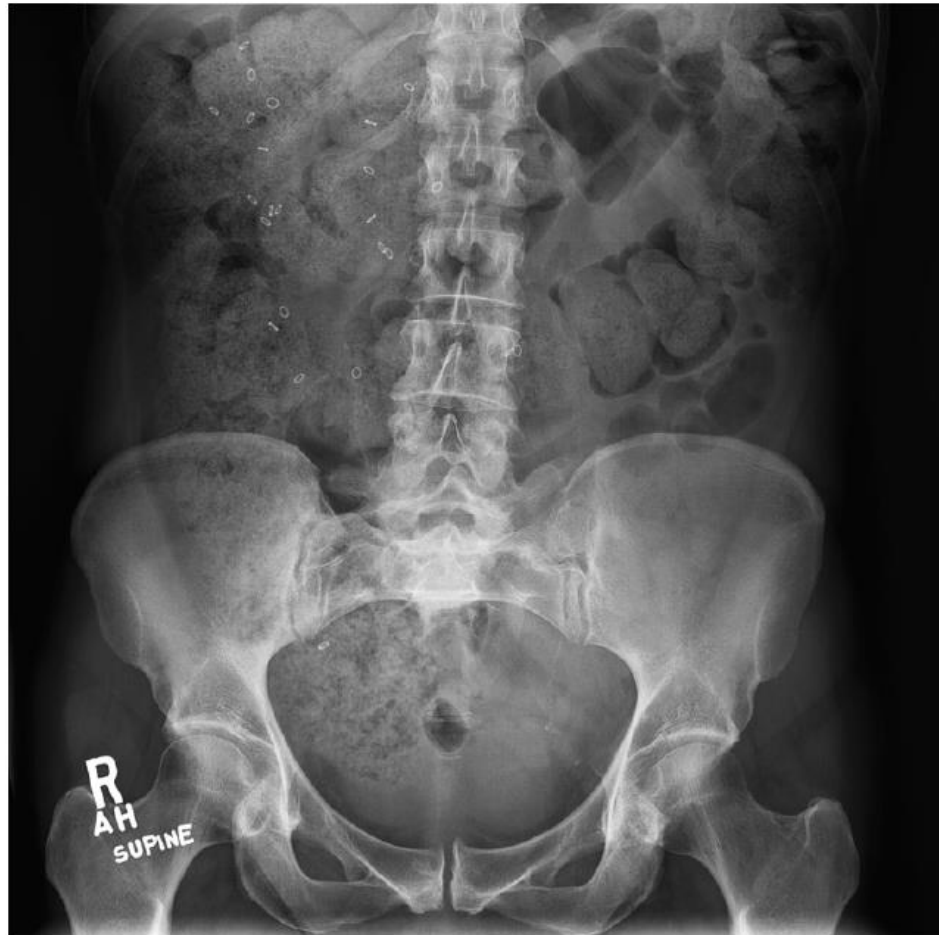# Needle EMG of the external sphincter

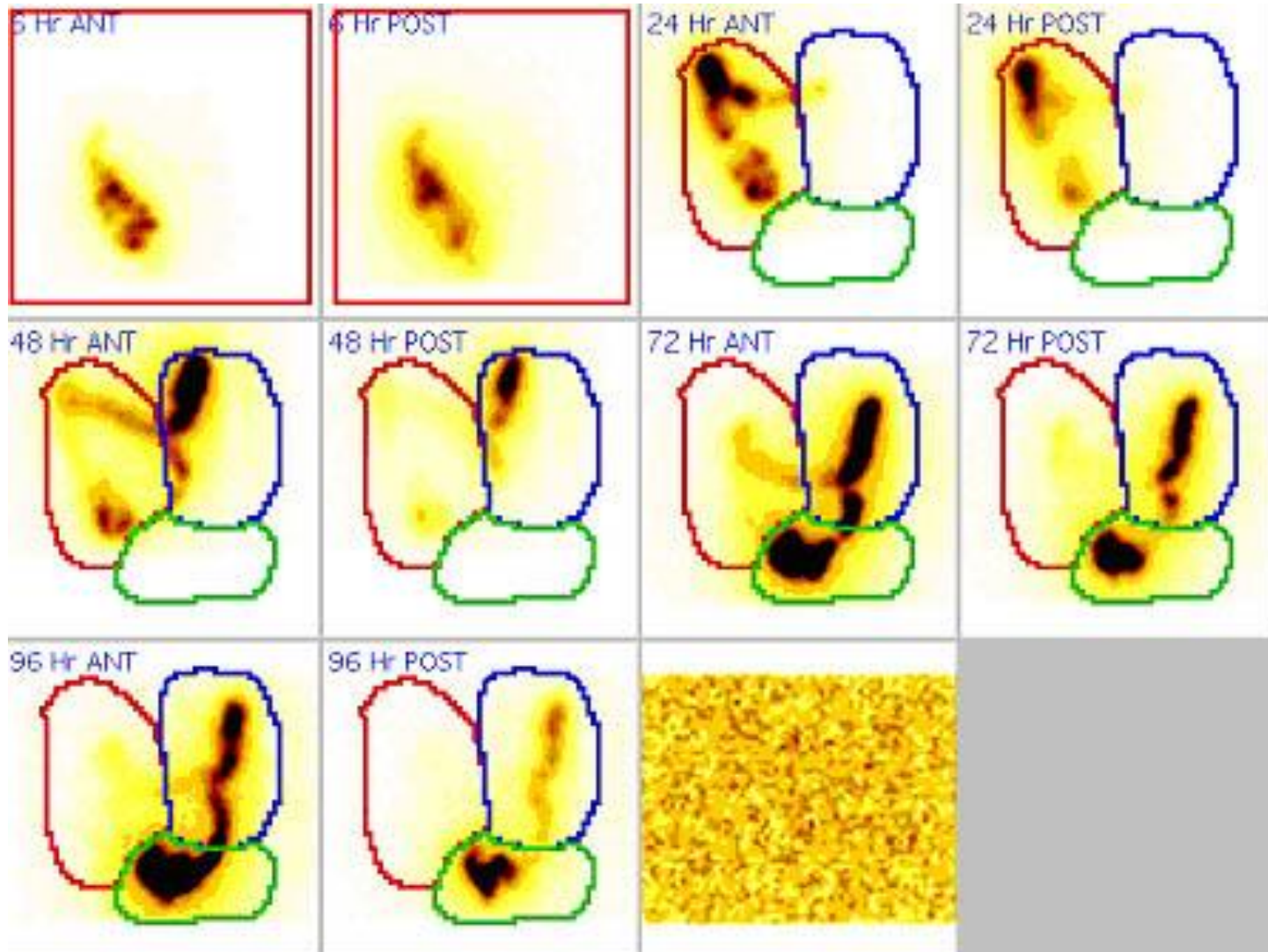


# Colon Transit Time





# CTT Scintigraphy



# CTT- wireless capsule

